

Barry P. McMahon, Jens B. Frøkjær, Peter Kunwald, Donghua Liao, Peter Funch-Jensen, Asbjørn M. Drewes and Hans Gregersen

Am J Physiol Gastrointest Liver Physiol 292:377-384, 2007. First published Aug 31, 2006;
doi:10.1152/ajpgi.00311.2006

You might find this additional information useful...

This article cites 25 articles, 8 of which you can access free at:

<http://ajpgi.physiology.org/cgi/content/full/292/1/G377#BIBL>

This article has been cited by 2 other HighWire hosted articles:

Biomechanical functional and sensory modelling of the gastrointestinal tract

D. Liao, D. Lelic, F. Gao, A. M. Drewes and H. Gregersen
Phil Trans R Soc A, September 28, 2008; 366 (1879): 3281-3299.

[\[Abstract\]](#) [\[Full Text\]](#) [\[PDF\]](#)

Analysis of Abdominal Wounds Made by Surgical Trocars Using Functional Luminal Imaging Probe (FLIP) Technology

B. P. McMahon, D. O'Donovan, Donghua Liao, Jingbo Zhao, R. Schiretz, R. Heninrich and H. Gregersen

Surgical Innovation, September 1, 2008; 15 (3): 208-212.

[\[Abstract\]](#) [\[PDF\]](#)

Updated information and services including high-resolution figures, can be found at:

<http://ajpgi.physiology.org/cgi/content/full/292/1/G377>

Additional material and information about *AJP - Gastrointestinal and Liver Physiology* can be found at:

<http://www.the-aps.org/publications/ajpgi>

This information is current as of December 7, 2009 .

The functional lumen imaging probe (FLIP) for evaluation of the esophagogastric junction

Barry P. McMahon,¹ Jens B. Frøkjær,¹ Peter Kunwald,² Donghua Liao,¹
Peter Funch-Jensen,³ Asbjørn M. Drewes,^{1,2} and Hans Gregersen^{1,2}

¹Centre for Visceral Biomechanics and Pain, Aalborg Hospital and ²Centre for Sensory Motor Interaction, Department of Health Science and Technology, Aalborg University, Aalborg, Denmark; and ³Department of Surgical Gastroenterology L, Aarhus University Hospital, Aarhus, Denmark

Submitted 14 July 2006; accepted in final form 29 August 2006

McMahon BP, Frøkjær JB, Kunwald P, Liao D, Funch-Jensen P, Drewes AM, Gregersen H. The functional lumen imaging probe (FLIP) for evaluation of the esophagogastric junction. *Am J Physiol Gastrointest Liver Physiol* 292: G377–G384, 2007. First published August 31, 2006; doi:10.1152/ajpgi.00311.2006.— There is a need for new methods to study the dynamics of the esophagogastric junction (EGJ). The aims were to verify the efficacy and usefulness of a “functional lumen imaging probe” (FLIP) for the evaluation of the EGJ. Eight healthy volunteers (6 men), median age 26 (21–35) yr, and two achalasia patients underwent the FLIP procedure. The EGJ was located by manometry. The FLIP measured eight cross-sectional areas (CSAs) 4 mm apart together with the pressure inside a saline-filled cylindrical bag. The data showed the geometric profile of the EGJ reconstructed in a video animation of its dynamic activity. A plot of curve-fitted data for the smallest CSA vs. pressure after balloon distension indicated that the pressure increased from 18 cmH₂O at a CSA of 38 mm² to a pressure of 37 cmH₂O at a CSA of 230 mm² for the healthy controls. In one achalasia patient (unsuccessfully treated with dilations), the CSA never rose above the minimal measurable value despite the pressure increasing to 50 cmH₂O. In another achalasia patient (successfully treated with dilations), the pressure only reached 15 cmH₂O despite opening to a CSA of 250 mm². In conclusion, FLIP represents the first dynamic technique to profile the function and anatomy of the EGJ. The method can be used practically to evaluate difficult cases of EGJ dysfunction and may provide a role in evaluating patients before and after therapies for diseases affecting the EGJ such as achalasia and gastroesophageal reflux disease.

esophagus; competence; distensibility; cross-sectional area; functional imaging

THE LOWER ESOPHAGEAL SPHINCTER (LES) is not solely responsible for impeding the flow between the esophagus and the stomach. The crural diaphragm encircles ~2 cm of the esophagogastric junction (EGJ), and the sling or oblique fibers of the stomach also contribute to the mechanism (15, 21). Esophageal and gastric motility, pressures in the abdominal and thoracic cavities, and the exact location of the EGJ all play a role in defining its function. The anatomy and behavior of the EGJ also change with time and body posture (20). The EGJ is a very dynamic mechanical structure. A lot of knowledge about the anatomy of the EGJ has been assembled over the last 40 years, but much of our limited understanding of the behavior has been related to manometric studies. Intraluminal pressure recording is the current gold standard for determining the motility characteristics of the esophagus. Although manometry provides

useful information on the location of the EGJ and on phasic motility within the lumens of the digestive tract, it may be more restrictive in what it can tell us about sphincteric regions and their dynamics.

Two classic diseases involving the EGJ are gastroesophageal reflux disease (GERD) and achalasia. Achalasia is an esophageal disorder of unknown cause characterized by aperistalsis of the esophageal body and impaired relaxation of the LES (4). Manometry has proven to be a useful tool in classic cases, but for early detection better measurement methods to determine sphincter function are needed. Harris and Pope (12) found that sphincters do not necessarily need to squeeze or contract tightly to be competent. Therefore resistance to distention should be the prime determinant of sphincteric strength. A measurement of the radial force applied from within the sphincter necessary to open it would provide a more meaningful guide to the evaluation of sphincter effectiveness. Manometric techniques are very limited in what they can tell us about radial force. Despite recent recommendations not to rely on manometry for certain diseased states, it is still used together with pH measurement and traditional imaging techniques to detect the pathology behind the cardinal abnormalities associated with disturbances in the EGJ function (22).

Usually in medicine dynamic diagnostic imaging methods such as ultrasound or barium studies using fluoroscopic imaging can be used to visualize and evaluate the EGJ. However, none of these imaging methods gives sufficient dynamic details to allow for the measurement of the radial force applied to the sphincter. Some attempts have been made over the years to address the inadequacies of the established measurement techniques. Parameters such as distensibility, opening patterns, dimensions, and flow rate may be important in understanding EGJ dynamics, but it is only in recent times that these characteristics associated with the EGJ's resistance to distention have been studied (23, 24, 27). On the basis of impedance planimetry, an already established technique for performing balloon distentions in the alimentary lumens, this work outlines the use of a functional lumen imaging probe (FLIP) (1, 2, 8–11, 26, 28). The probe combines measurements of the EGJ resistance to distention with geometric reconstruction of the EGJ (17, 18). This concept of measuring distensibility of the EGJ has already been considered by Pandolfino et al. (23).

We hypothesized that the FLIP would be able to give substantial new information about the EGJ in health and

Address for reprint requests and other correspondence: B. McMahon, Medical Physics & Clinical Engineering, Adelaide & Meath Hospital, Tallaght, Dublin 24, Ireland (e-mail: barry@mech-sense.com).

The costs of publication of this article were defrayed in part by the payment of page charges. The article must therefore be hereby marked “advertisement” in accordance with 18 U.S.C. Section 1734 solely to indicate this fact.

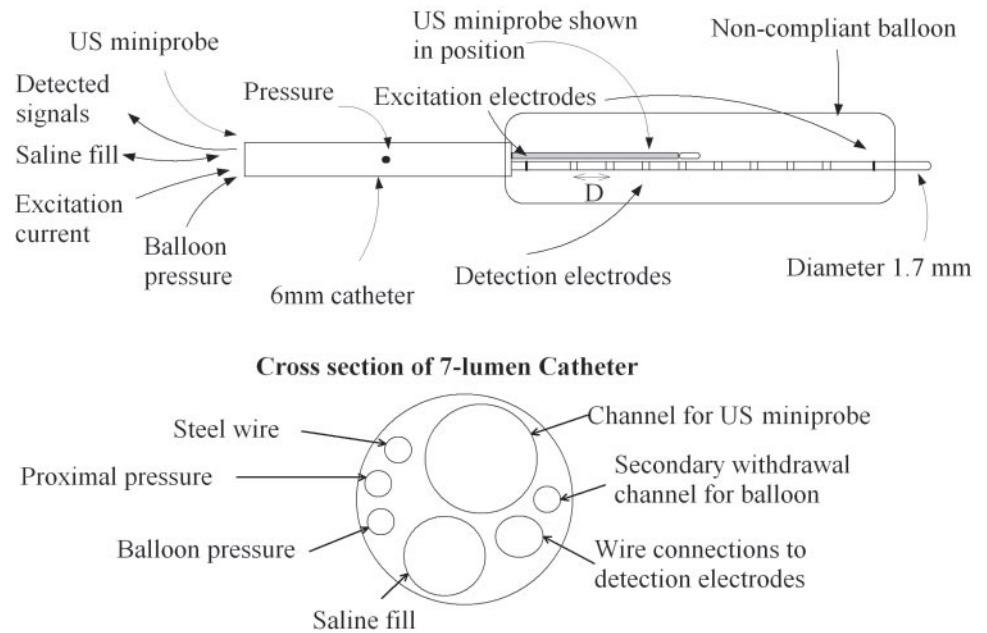


Fig. 1. Diagram of the functional lumen imaging probe (FLIP) showing the ultrasound (US) miniprobe in position and a cross section of the catheter tube. The distance (D) between the detection electrodes is 4 mm.

disease. The aims of this study were 1) to verify the efficacy and usefulness of the FLIP for the evaluation of the EGJ in healthy subjects, 2) to confirm location of FLIP with ultrasound imaging of the EGJ, and 3) to compare the ability of the FLIP in determining EGJ characteristics from data on healthy controls with preliminary data on two achalasia patients.

MATERIALS AND METHODS

Subjects. Eight volunteers (6 men), mean age 26 (21–35) yr were recruited for this study. Volunteer inclusion criteria were age 35 yr old or less, nonsmoking, with no history of reflux, heartburn, or regurgitation. Subjects were healthy; they had no previous gastrointestinal surgery and were taking no prescribed medication.

Two achalasia patients were recruited for the pilot study. Both were balloon dilated under fluoroscopic guidance with a 30-mm dilator balloon (Rigiflex II, Boston Scientific, Natick, MA) inflated until the balloon unfolded fully. This was done at least twice in the previous 12 mo. *Patient 1* was a man aged 28 yr with dysphagia for 18 mo. On manometric investigation before dilation the lower esophageal sphincter pressure was 50 mmHg (67 cmH₂O), and relaxation was incomplete. A method of determining differences in the pressure changes at three points in the distal part of the esophagus as the subject rapidly swallows 180 ml of contrast continuously, known as the swill test, was also positive for achalasia (7). In the smooth muscled corpus only nonperistaltic, low-amplitude (<30 mmHg) repetitive deflections were noted. At endoscopy the esophagus was slightly dilated and the cardia region closed. There was no saliva or food retention. The patient was previously dilated three times (8, 9, and 11 mo before investigation), with transient (1–2 wk) effect. *Patient 2* was a man aged 60 yr with a lower esophageal sphincter pressure 41 mmHg (55 cmH₂O) before dilation and incomplete relaxation of the sphincter upon swallowing. He suffered from dysphagia for 12 mo. Swill test was positive for achalasia. In the smooth muscle esophagus only nonperistaltic, repetitive contractions with amplitudes up to 50 mmHg (67 cmH₂O) were measured after wet swallows. Upon endoscopy it was noted that the esophagus was slightly to moderately dilated and there was retention of saliva. It was further noted that the cardia region was contracted.

The study was carried out with Local Ethics Committee approval (protocol no. VN 2003/120mch), and informed consent was obtained.

The probe. The FLIP was custom designed to measure eight cross-sectional areas (CSAs) and two manometric pressures and to facilitate the insertion of a 1.7-mm diameter, 20 MHz radial scanning ultrasound miniprobe model (UM-3R, Olympus, Tokyo, Japan, Fig. 1) used for validation. The length of the probe was 72 cm with 60 cm toward the proximal end constructed from a seven-lumen polyurethane tube with an outer diameter of 6 mm. The distal 12 cm of the probe, which lies inside and distal to the bag, was constructed of a two-lumen polyethylene catheter with an outer diameter of 1.6 mm.

An excitation constant current of 100 μ A at a frequency of 5 kHz was generated from a source in the data-acquisition system (GMC Medical, Hornslet, Denmark). The current was delivered to two excitation electrodes located on each side of the multiple detection electrodes. Voltage measurements were made across eight electrode pairs, each electrode in the pair was 1 mm from the other, and the distance from the center of one pair to the next, i.e., the distance between measurements, was 4 mm. The voltage measured was proportional to the impedance between the sensing electrodes, which increased as the bag filled with saline (18). This impedance change was therefore proportional to the CSA change at each sensing pair in the bag. The bag was infinitely compliant to an inflated diameter of 3.2 cm. The cylindrical bag length when mounted on the probe was 10 cm, and the bag ends were folded in before being affixed to the catheter. This creates a rolling-bag effect whereby, when the bag was inflated, the catheter can move longitudinally through 3 cm without dislodging the bag. The channels in the catheter could be perfused with saline and were used to make manometric pressure measurements using a low-compliance perfused system connected to external transducers (Edwards TruWave, Edwards Lifesciences, Irvine, CA). Pressure measurements were made proximal to and inside the bag. The ultrasound miniprobe was connected to an ultrasound processing and imaging system (EU-M30 Olympus, Tokyo, Japan); the output video signal was connected to and directly captured by a digital video frame grabber with appropriate software (Studio 8, Pinnacle Systems).

Data analysis. The measured voltages from the eight electrode pairs and the pressure transducers was amplified and digitized by using the data-acquisition system. The data were collected at a sampling rate of 10 Hz and transmitted to a personal computer. Data were displayed on the personal computer by a custom-made data-acquisition software system programmed in Labview version 6.1. (National Instruments, Austin, TX). Software was developed using

MATLAB version 6.5 (Natick, MA) for data analysis, plotting, and three-dimensional rendering.

Device calibration. A set of polymethylmethacrylate (Perspex) cylindrical tubes with CSAs of 38.5, 73.8, 132.7, 201, 283.5, and 572 mm² was used to calibrate the FLIP. The FLIP was filled with a 0.225 g/l saline solution and left in a 37°C water bath for a short time to reach body temperature. While the FLIP and the calibration tubes were immersed in the water bath, the bag was deflated. Starting with the largest cylinder the probe was placed so that the balloon was completely inside the tube and kept parallel to the cylinder wall. The bag was inflated until it fitted tightly to the inner walls of the tube. The software was configured in calibration mode. The calibration voltage was automatically recorded for 10 s, and the average voltage recorded was converted to the CSA value of the respective tube in square millimeters. This procedure was repeated for each tube in descending order of size. A calibration curve was then generated for each CSA by using a linear point curve-fit method, and the calibration was stored, leaving the FLIP ready for use. This calibration procedure was carried out immediately before each study.

Volunteer procedure. The protocol is shown in Fig. 2. The FLIP was inserted orally and moved forward until the balloon, mounted toward the distal end, traveled all the way into the stomach so that the distance from the nares to the distal tip of the balloon was 60 cm. Once the FLIP was inserted the subjects were allowed at least 20 min to relax after being put in the supine position with the head tilted slightly forward, where they remained for the duration of the study.

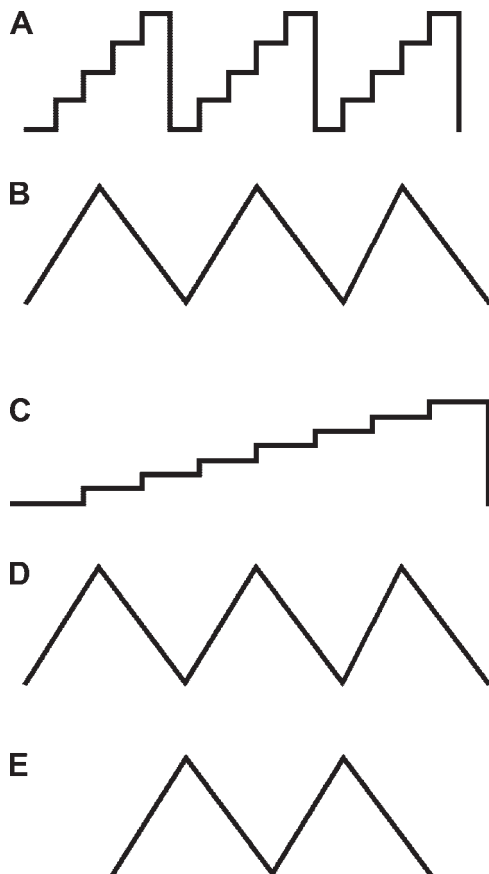


Fig. 2. Flow diagram for volunteer protocol starting with 3 manometry pull-throughs (A) to identify point of respiratory inversion followed by 3 preconditioning distentions (B). This was followed by stepwise volume distentions to 60 ml in which the ultrasound probe was used for scanning at each detection electrode pair (C). Three distentions at 40 ml/min to 60 ml were then performed (D). Finally, 2 further distentions were done to 60 ml after the administration of butylscopolamine to relax the smooth muscle (E).

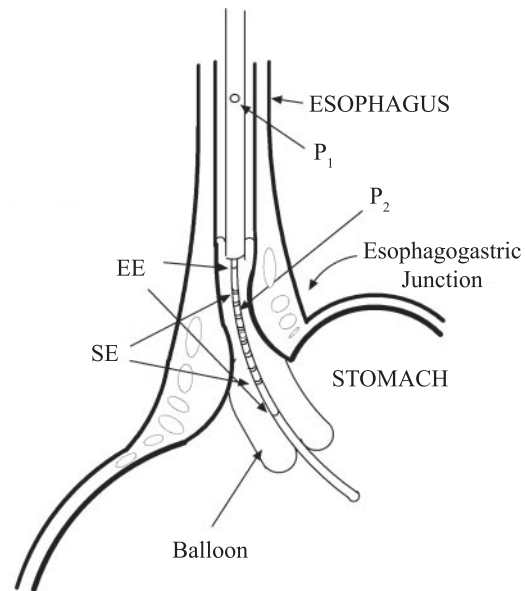


Fig. 3. Illustration showing the FLIP in position straddling the esophagogastric junction (EGJ). Manometric pressures are measured proximal to the balloon (P_1) and inside the balloon (P_2). Measurement is activated by a current across the excitation electrodes (EE) and the cross-sectional area can be measured across the 8 sensing electrodes (SE).

Three reverse-step pull-throughs at 1-cm intervals were performed from this point, and the lower esophageal sphincter high-pressure zone and the respiratory inversion point were identified by using the perfused hole proximal to the bag containing the CSA electrodes. The respiratory inversion point is where positive pressure in the abdominal cavity due to respiratory fluctuations becomes negative as the manometric measurement point moves into the thoracic cavity. The distance from the distal tip of the probe to the respiratory inversion point was noted. The average distance to the distal tip measured for the three pull-throughs was recorded and used as the distance to place the center of the eight-electrode array for measuring CSA so that the balloon straddled the EGJ (Fig. 3). At least two preconditioning distentions were performed by infusing the balloon with the $2.2 \times 10^{-4}\%$ saline concentration at a rate of 40 ml/min. The criterion for stopping all distentions was either when the volunteer reached the threshold of pain sensation or when the balloon volume reached 60 ml using the same solution. A series of volume-controlled step distentions were then carried out at volumes of 20, 30, 40, 50, and 60 ml. At each volume step the ultrasound miniprobe was positioned at the most distal electrode pair in the FLIP and images were recorded. Marks were concurrently made on the CSA tracings from the FLIP and the ultrasound images to synchronize them in time. The probe was then moved successively to the next most proximal CSA measurement pair and the ultrasound image was recorded and synchronized with the FLIP data. At each volume two swallows of 5 ml of water were carried out. For the first swallow the volunteers inhaled and held their breath before swallowing and before the second swallow they exhaled and held their breath. The process was repeated until ultrasound images were recorded at all eight CSA measurement points, and swallows were obtained at all volumes tolerated by the volunteers up to 60 ml. The scanning was also used to confirm the presence or absence of a hiatal hernia in all subjects.

Three volume-controlled distentions at 40 ml/min with concomitant measurement of CSA and pressure were then carried out to the point of pain detection threshold or to a maximum volume of 60 ml, whichever came first. The subjects were then administered 20 mg of

butylscopolamine to block cholinergic-mediated contractile smooth muscle activity. A further two volume-controlled distentions were then carried out at 40 ml/min to the point of pain sensation or to a maximum volume of 60 ml. During all distention the subjects were asked to refrain from swallowing. If swallowing did occur the distention was repeated.

Achalasia patient procedure. The FLIP was inserted nasally and guided down the esophagus under fluoroscopic control. As before, the probe was moved forward until the balloon section traveled all the way into the stomach so that the distance from the nares to the distal tip of the balloon was 60 cm. The FLIP was then retracted until the detection electrodes on the probe were in position straddling the EGJ as viewed fluoroscopically. The distance from the tip of the nose to the end of the probe was noted. No manometric pull-throughs were performed on the patients because there was a danger of dislodging the probe into the esophagus. When the probe was in position the patients relaxed for 20 min and then a number of preconditioning distentions were carried out as per the volunteer protocol; from this point on the protocol on patients was the same as for the volunteers described earlier except that no ultrasound pull-throughs were performed because of difficulties in probe placement.

RESULTS

The LES and the respiratory inversion point were identified by manometry in all volunteers. The median LES pressure was 32 (26–55) cmH₂O. In all but one of the volunteers the respiratory inversion point was found to identify the narrowest point through the EGJ during distention. In some cases the probe was moved proximally or distally by 1 cm to optimize the position. In the achalasia patients the FLIP was successfully placed in the EGJ when guided by the fluoroscopic image. None of the study subjects had a hiatal hernia.

Anatomy of the EGJ. The two-dimensional EGJ geometry for the eight volunteers is shown in Fig. 4. It can be seen that over a 28-mm distance in the area of the high-pressure zone the geometry varied considerably. The ultrasound measurements made at stepped volumes confirmed that the point at which the detection electrodes were placed correlated well with the muscle thickening region found at the EGJ in all the volunteers. An

example is shown in Fig. 5. This region correlated well with the high-pressure zone in all but one of the volunteers (*volunteer 5* in Fig. 4). After a number of exploratory distentions in this volunteer the EGJ was found ~3 cm lower than identified by the pull-through. This position was confirmed by ultrasound. Analysis of the tracings suggests that, because of very active peristaltic movements, it was difficult to detect the high-pressure zone in the EGJ from contractions in the nearby distal esophagus, illustrating the limitations of single-point-sensing manometry.

Compliance data. Figure 6 shows a plot of the pressure-volume relationship during distentions from 0 to 60 ml for the volunteers and the two achalasia patients. From the plot the sphincters of the volunteers appeared to relax under less pressure, displaying a rather linear increase in pressure with increase in volume. *Patient 1* had a similar overall pattern to pressure increase as the volunteers but there were increasing and decreasing fluctuations of as much as 20 cmH₂O. This suggests that the noncompliant sphincter resists the increase in volume brought on by distention, causing a pressure increase, and then the sphincter relaxes slightly, allowing flow-through and causing a pressure drop. *Patient 2* appears from this plot to show little or no resistance to distention despite the volume increase as demonstrated by the low pressure even at high volume. Figure 7, on the other hand, shows a plot of pressure vs. CSA data. This demonstrates how the narrowest CSA measured across the eight electrodes related to the balloon pressure measurement during the volume-controlled distention. *Curve A* shows the fitted data for the eight volunteers. *Curve B* shows a small decrease in the pressure curve for the volunteers after the administration of butylscopolamine; this is most likely due to its anticholinergic effect causing the EGJ to be more compliant as its wall gets pushed further out. *Curve C* indicates the profile of *patient 1*. A clear distinction exists between the volunteers and this patient. The achalasia patient is seen to maintain the smallest measurable CSA despite the increase in pressure brought on by volume-controlled disten-

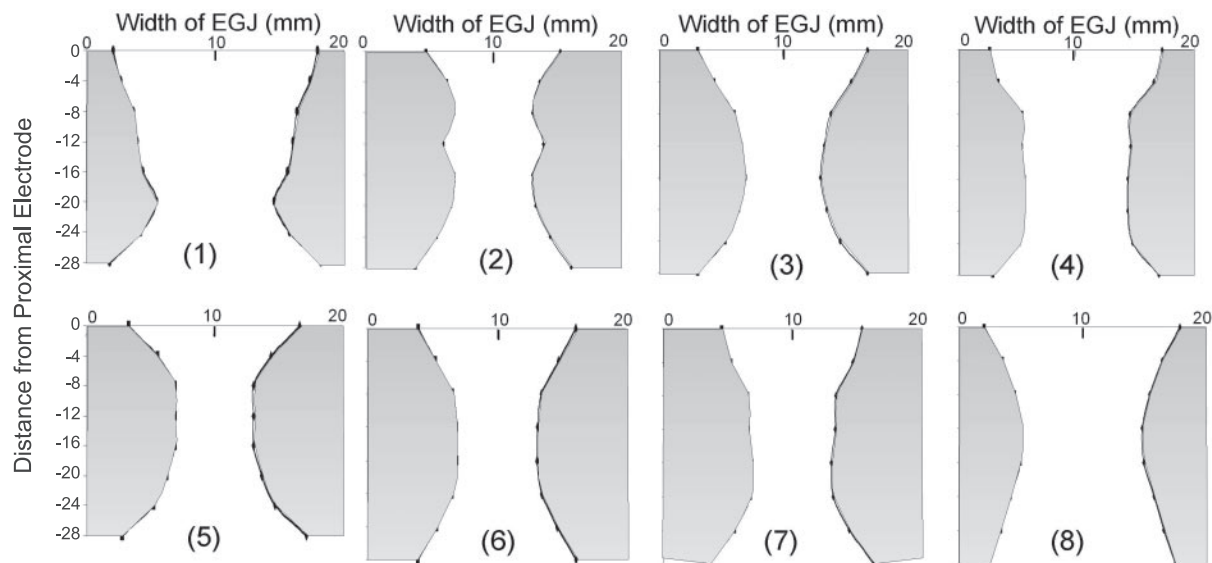


Fig. 4. Charts showing 2-dimensional plots of the diameter measured for all volunteers (1–8) taken from normal distention data at a pressure of 20 cmH₂O (distance in x-axis in mm).




Fig. 5. Ultrasound image taken in which the FLIP straddles the esophagogastric junction confirmed by the presence of esophageal muscle thickening in the junction.

tion. *Curve D* shows that for *patient 2* an increase in CSA does not show a corresponding increase in pressure, suggesting that for this patient very little tension is generated in the EGJ.

The longitudinal location of the narrowest point in the EGJ was recorded from the ultrasound measurements at different distention volumes. All the volunteers showed a pattern where the narrowest point migrates toward the proximal end of the CSA measurements, suggesting that the esophagus is shortening and/or that the EGJ opens from the stomach.

Functional imaging. From CSA data during distentions at 40 ml/min a three-dimensional image of functional geometry through the EGJ was constructed in video animation format. An example of an image of a typical pattern for all the volunteers is shown in Fig. 8A. Here the narrowest point migrated toward the proximal end of the CSA, which was also indicated in the data from the ultrasound pictures. Data were also reconstructed in the same manner for distentions in *patient 1* (Fig. 8B). The reconstructed data in Fig. 8, A and B indicate how functional lumen imaging data can clearly distinguish

between a normal and a diseased EGJ. The profile for the volunteer in Fig. 8A shows how the sphincter is more compliant and the CSA increases gradually at the narrowest point as the volume increases. This is not the case in Fig. 8B, where the narrowing region of the EGJ remains at a small CSA right up to the 60-ml distention volume. Although the images in Fig. 8 demonstrate how the data can be used, these still images do not fully illustrate how this technique demonstrates the dynamic action of the EGJ, which can be seen on video at <http://www.mech-sense.com/computerstim.htm>.

DISCUSSION

The FLIP technique represents the first method by which the function and anatomy of the EGJ can be quantified in the same experiment. In the present work it was determined that the FLIP can be used practically to determine the dynamic profile of the EGJ. By providing CSA-pressure curves, FLIP was

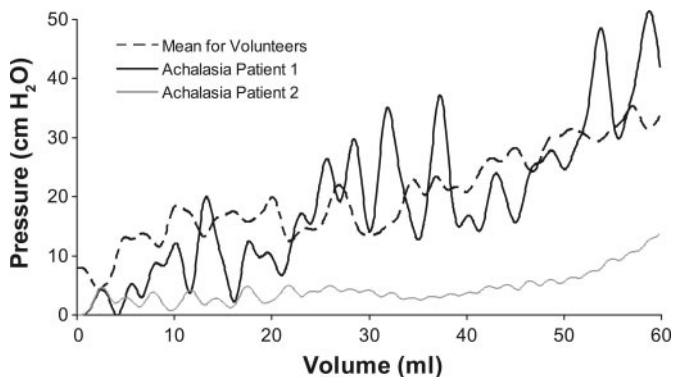


Fig. 6. Pressure plotted against volume during 40 ml/min distentions for mean of volunteers and the achalasia patients.

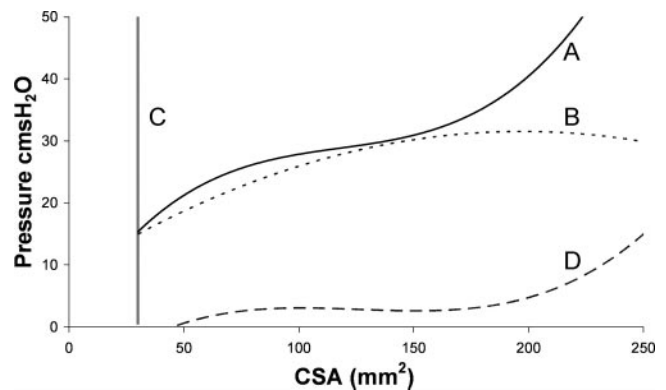


Fig. 7. Pressure plotted against the narrowest cross-sectional area from volume distentions at 40 ml/min showing fitted data for volunteers before (A) and after butylscopolamine (B) and the achalasia *patient 1* (C) and achalasia *patient 2* (D).

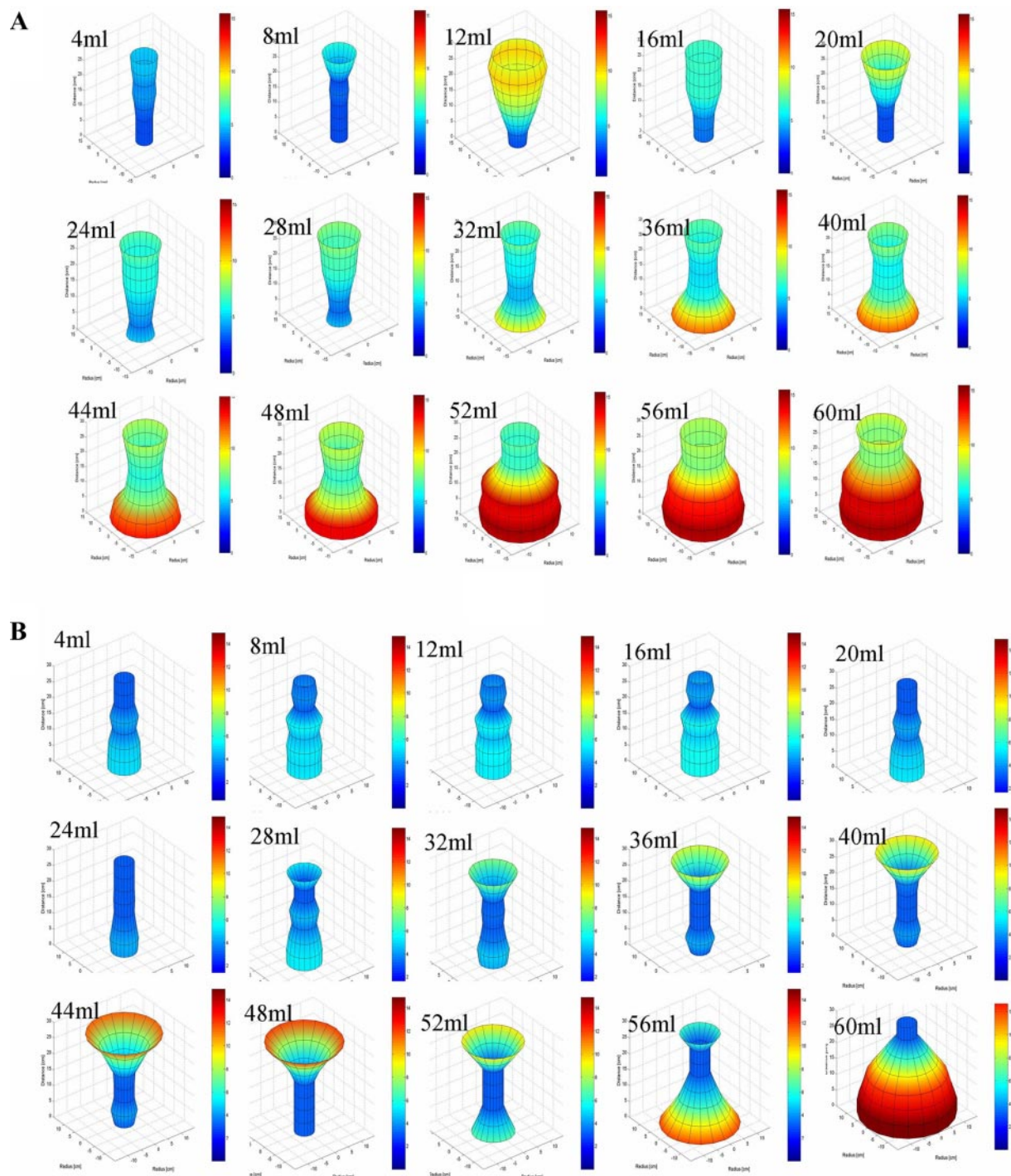


Fig. 8. Still images from 3-dimensional reconstructed data of cross-sectional areas of a normal volunteer (A) and achalasia patient 1 (B) in the esophagogastric junction at different volumes during ramp distension from 0 to 60 ml. X, Y, and Z dimensions in all images are in millimeters; color bar indicates increase in radius from 0 mm (blue) up to 15 mm (brown) by color change.

superior to manometry for determining EGJ characteristics and provides much better information on its action. Use of this new technique was confirmed by using radial scanning ultrasound. The data presented shows that pressure-volume relationships are not adequate for denoting the differences between achalasia sufferers and normal controls. FLIP may be usable in patients where substantial new information can be used to guide the

clinician toward better therapy based on the patient's dynamic distention profile.

The limitations of manometry. Since the seminal works of Code et al. (5) and Ingelfinger (13) in the 1950s, it has been common practice to use manometry to quantify function at the EGJ. However, the concept that a sphincter prevents flow by creating a barrier of pressure is limited. This has been demon-

strated in recent works in which manometry was unable to identify different patterns of reflux in patients with different posture and time patterns (20). Manometric quantification of the EGJ is based on the principle that the junction maintains a force or a "squeeze" when it is contracted. However, it cannot be assumed that the EGJ exerts a force perpendicular to the lumen when it is closed. As an example, the action of EGJ can be considered as a sliding door. It takes a lateral force to open or close the door but when the door is closed it can resist a perpendicular force without the radial force. If the EGJ acts like a sliding door when closed then a technique such as manometry, which measures the presence of a lateral force, would be of less value to determine its characteristics. Resistance to distention is, as suggested by Harris and Pope (12), a better marker for quantifying sphincter function than squeeze or tonic contraction. More recently this idea has been explored by other researchers, indicating that differences between normal controls and patients with diseases of the EGJ show differences in their pressure-geometry characteristics during distensions (14, 19, 27).

Advantages of CSA-pressure data. The present technique has its basis in the concepts developed by Biancani et al. (3) showing an advancement on the basic manometric technique by measuring pressure in the sphincter using different probe diameters. A preliminary use of impedance planimetry to measure CSA in the EGJ was considered by Patel et al. (25). However, keeping the balloon in position at higher pressures proved difficult with a spherical-shaped balloon, and, although a narrowing of the lower esophageal region was observed, it would have been difficult to determine whether the CSA was measured at the optimal position. They used a form of resistance to distention that was able to distinguish between normal and incompetent sphincters. Pandolfino et al. (23) have recently demonstrated how measuring pressure and diameter can contribute to determination of the sphincter competence. The results from the healthy controls in our work correlate well with their study. However, data from the FLIP technique are easier to analyze and provide objective data in real time without use of ionizing radiation as in the study by Pandolfino et al. Not only did our technique demonstrate how LES tone and crural diaphragm activity affected the recording of distensibility, but the FLIP technique provided a method to visualize their effects in real time and in three dimensions. It is very difficult in practice to control pressure in the EGJ. Although our pressure-volume results broadly concur with those of Shaker et al. (27), we do not agree that the rate of change of volume over rate of change in pressure is a suitable measure of distensibility of the EGJ. From our data multiple pressure-CSA relations are more useful and have a sound basis in the physical sciences (27). Our findings in relation to reduced compliance in the achalasia patient concur with the results from Mearin et al. (19), who used a resistance-to-flow rather than a resistance-to-distention technique.

Subjects. The data from healthy volunteers demonstrated the anatomical action of the junction identifying previously immeasurable parameters such as the narrowest point, the dynamic movement during bag distention, and reconstructing the geometry of the EGJ in an animated video. It is quite easy to confirm achalasia with manometry, but it may be less straightforward to diagnose differences in individual cases and to get a detailed analysis of the effects of dilatation or

other treatment regimes. These new data measured with FLIP suggest that *patient 1* had only received transient relief from dilatation three times in the year previous to our study. In this case the FLIP data confirmed that his sphincter remains tightly closed up to a pressure of 50 cmH₂O, and the CSA-pressure curves together with the dynamic profiles demonstrated the sphincter dysfunction with high accuracy. *Patient 1* had been dilated multiple times and still demonstrates symptoms of achalasia such as a high LES pressure. However, with FLIP we demonstrated that as the CSAs increased during balloon distension, the pressure remained low in the balloon, indicating that the force exerted on the balloon by the EGJ is very low and hence sphincter contraction force must be very low. Perhaps this patient has another, less classical manifestation of the disease, and it is possible that our findings could be of benefit in the selection of a treatment modality. Hence, a technique such as FLIP may provide better information on what treatment technique to use by providing a better understanding of sphincter dynamics in the diseased state.

Limitations and future improvements. As with any other invasive technique, we may have disturbed the function of the EGJ. However, since this is a provocative distention test rather than a test of contraction or squeeze such as manometry is, this may not be a significant problem. The true value of these data can be better represented on a video image. In this case the video images were generated after data collection, but technological developments will not restrict the reconstruction of these images in real time. Although the resolution of the CSA profiles was good, the technique would benefit more by increasing the number of detection points and therefore the number of CSAs measured through the EGJ. This is technically possible and would also give the possibility for increasing the measurement range. Pressure measurement in the bag was from the most proximal end, and this may have been a source of error if the bag does not form a common cavity.

Conclusions and perspectives. The present work represents an entirely new technique for dynamic evaluation of the EGJ. Measurement with the FLIP can be as easily performed as a manometric study. The study demonstrates that the FLIP can be placed in the EGJ and that it gives substantial new and detailed information about the EGJ in health and disease. Further studies will help evaluate the full usefulness of the technique. It may be of benefit in determining the competence of the EGJ in patients with, e.g., achalasia and GERD. There may also be benefits in evaluating patients undergoing surgery and endoscopic therapies for such diseases in which the patients could be monitored before, during, and after treatment. It could for example be used down the working channel of an endoscope to determine the effects of endotherapies on reflux disease (6, 16). This technique may also be useful in other sphincteric regions in the digestive tract and thus may become an important clinical instrument.

GRANTS

This work was funded in part by grants from the Obel and Spar Nord Foundations.

REFERENCES

1. Assentoft JE, Gregersen H, O'Brien WD Jr. Determination of biomechanical properties in guinea pig esophagus by means of high frequency ultrasound and impedance planimetry. *Dig Dis Sci* 45: 1260–1266, 2000.
2. Barlow JD, Gregersen H, Thompson DG. Identification of the biomechanical factors associated with the perception of distension in the human esophagus. *Am J Physiol Gastrointest Liver Physiol* 282: G683–G689, 2002.
3. Biancani P, Zabinski MP, Behar J. Pressure tension, and force of closure of the human lower esophageal sphincter and esophagus. *J Clin Invest* 56: 476–483, 1975.
4. Castell DO, Richter JE. *The Esophagus*. Boston, MA: Lippincott Williams & Wilkins, 2004.
5. Code CF, Fyke FE Jr, and Schlegel JF. The gastroesophageal sphincter in healthy human beings. *Gastroenterologia* 86: 135–150, 1956.
6. Filipi C, Lehman G, Rothstein R, Rajjman I, Stiegmann G, Waring JP, Hunter J, Gostout C, Edmundowicz S, Dunne D, Watson P, Cornet D. Transoral, flexible endoscopic suturing for treatment of GERD: a multicenter trial. *Gastrointest Endosc* 53: 416–422, 2001.
7. Funch-Jensen P, Aksglaede K, Thommesen P. A new method for the detection of incomplete lower esophageal sphincter relaxation in patients with achalasia. *Scand J Gastroenterol* 35: 349–352, 2000.
8. Gregersen H. *Biomechanics of the Gastrointestinal Tract: New Perspectives in Motility Research and Diagnostics*. London: Springer-Verlag, 2003.
9. Gregersen H, Christensen LL. Pressure-cross-sectional area relations and elasticity in the rabbit oesophagus in vivo. *Digestion* 57: 174–179, 1996.
10. Gregersen H, Kassab G. Biomechanics of the gastrointestinal tract. *Neurogastroenterol Motil* 8: 277–297, 1996.
11. Gregersen H, Vinter-Jensen L, Juhl CO, Dajani EZ. Impedance planimetric characterization of the distal oesophagus in the Goettingen minipig. *J Biomech* 29: 63–68, 1996.
12. Harris LD, Pope CE 2nd. "Squeeze" vs. resistance: an evaluation of the mechanism of sphincter competence. *J Clin Invest* 43: 2272–2278, 1964.
13. Ingelfinger FJ. Esophageal motility. *Physiol Rev* 38: 533–584, 1958.
14. Jenkinson AD, Scott SM, Yazaki E, Fusai G, Walker SM, Kadiramanathan SS, Evans DF. Compliance measurement of lower esophageal sphincter and esophageal body in achalasia and gastroesophageal reflux disease. *Dig Dis Sci* 46: 1937–1942, 2001.
15. Liebermann-Meffert D. What anatomic structures are undoubtedly responsible for gastroesophageal competence? In: *The Esophagogastric Junction*, edited by Guili R, Galmiche J, Jamieson G, and Scarpignato C. London: John Libbey Eurotext, 1998, p. 3–6.
16. Mahmood Z, McMahon BP, Arfin Q, Byrne PJ, Reynolds JV, Murphy EM, Weir DG. Endocinch therapy for gastro-oesophageal reflux disease: a one year prospective follow up. *Gut* 52: 34–39, 2003.
17. McMahon BP, Frokjaer JB, Drewes AM, Gregersen H. A new measurement of oesophago-gastric junction competence. *Neurogastroenterol Motil* 16: 543–546, 2004.
18. McMahon BP, Frokjaer JB, Liao D, Kunwald P, Drewes AM, Gregersen H. A new technique for evaluating sphincter function in visceral organs: application of the functional lumen imaging probe (FLIP) for the evaluation of the oesophago-gastric junction. *Physiol Meas* 26: 823–836, 2005.
19. Mearin F, Fonollosa V, Vilardell M, Malagelada JR. Mechanical properties of the gastro-esophageal junction in health, achalasia, and scleroderma. *Scand J Gastroenterol* 35: 705–710, 2000.
20. Meining A, Fackler A, Tzavella K, Storr M, Allescher HD, Klausner A, Heldwein W. Lower esophageal sphincter pressure in patients with gastroesophageal reflux diseases and posture and time patterns. *Dis Esophagus* 17: 155–158, 2004.
21. Mittal RK, Balaban DH. The esophagogastric junction. *N Engl J Med* 336: 924–932, 1997.
22. Pandolfino JE, Kahrilas PJ. AGA technical review on the clinical use of esophageal manometry. *Gastroenterology* 128: 209–224, 2005.
23. Pandolfino JE, Shi G, Curry J, Joehl RJ, Brasseur JG, Kahrilas PJ. Esophagogastric junction distensibility: a factor contributing to sphincter incompetence. *Am J Physiol Gastrointest Liver Physiol* 282: G1052–G1058, 2002.
24. Pandolfino JE, Shi G, Truworthy B, Kahrilas PJ. Esophagogastric junction opening during relaxation distinguishes nonhernia reflux patients, hernia patients, and normal subjects. *Gastroenterology* 125: 1018–1024, 2003.
25. Patel RS, Rao SSC. Biomechanical and sensory parameters of the human esophagus at four levels. *Am J Physiol Gastrointest Liver Physiol* 275: G187–G191, 1998.
26. Rao SS, Gregersen H, Hayek B, Summers RW, Christensen J. Unexplained chest pain: the hypersensitive, hyperreactive, and poorly compliant esophagus. *Ann Intern Med* 124: 950–958, 1996.
27. Shaker R, Bardan E, Gu C, Massey BT, Sanders T, Kern MK, Hoffmann RG, Hogan WJ. Effect of lower esophageal sphincter tone and crural diaphragm contraction on distensibility of the gastroesophageal junction in humans. *Am J Physiol Gastrointest Liver Physiol* 287: G815–G821, 2004.
28. Villadsen GE, Storkholm J, Zachariae H, Hendel L, Bendtsen F, Gregersen H. Oesophageal pressure-cross-sectional area distributions and secondary peristalsis in relation to subclassification of systemic sclerosis. *Neurogastroenterol Motil* 13: 199–210, 2001.